

RESEARCH COMMUNICATION

Chemopreventive Potential and Safety Profile of a *Curcuma longa* Extract in Women with Cervical Low-Grade Squamous Intraepithelial Neoplasia

JV Joshi^{1,2}, PH Paradkar^{1,2}, SS Jagtap², SV Agashe¹, G Soman³, AB Vaidya¹

Abstract

Objective: To determine whether *Curcuma longa* Linn extract, NBFR-03, can arrest low-grade squamous intraepithelial neoplasia (LSIL) a 12 week intervention study was performed. **Methods:** Of a total of 1473 women undergoing Pap smear screening, 88 cases had LSIL. Only those with persistent LSIL subsequent to antimicrobial therapy, and willing to follow the protocol (N=21), were included for clinical examination, Pap smears, colposcopy, clinical biochemistry, urinalysis and assessment of serum IL-6, being conducted before and after treatment. Standardised NBFR-03 (0.2gm) capsules were administered, twice daily, for 12 weeks. **Results:** None progressed to higher grade lesion as assessed by Pap smears and colposcopy. Sixteen cases regressed to atypia, ASCUS or inflammatory pattern; 3 persisted as LSIL, 1 discontinued early because of itching, and 1 did not start. None developed any significant abnormality clinically or biochemically. Micrometry showed a significant reduction in nuclear diameter and nucleocytoplasmic ratio after treatment ($p < 0.02$, and < 0.05 respectively). Serum IL-6 levels showed a significant decline (mean 248 ± 156 (SEM) vs 27.7 ± 10.5 (SEM) pg/ml; $p < 0.05$). **Conclusion:** Use of NBFR-03 for 12 weeks was associated with an arrest or regression of LSIL in Pap smears and colposcopy, with reduction in the circulating IL-6 levels.

Key words: Chemoprevention - cervical LSIL - NBFR-03 - turmeric extract - Pap smears - *Curcuma longa* Linn

Asian Pacific J Cancer Prev, 12, 3305-3311

Introduction

Cervical cancer is a frequent cause of death and morbidity in women, particularly in developing countries (Moore et al., 2010). Primary prevention by immunization against high risk human papilloma virus (HPV) subtypes 16/18 is possible and its safety and long term efficacy is under investigation. However, even if it succeeds it will take another 25 years to cover the young target population, and it may prevent only 70 % of cervical cancers (Cuzick et al, 2010). Moreover, already several millions of women are infected with HPV and are being screened by Papanicolaou smears / HPV DNA for cancer and for precancerous conditions or intraepithelial neoplasia (Sankaranarayanan & Boffetta, 2010). Treatment of precancer is more cost-effective than treatment of cancer, and more importantly, less painful and with a better quality of life for women. This study was directed towards the diagnosis and potential treatment modality of the earliest phase of precancer detected in Papanicolaou (Pap) smears, technically called as low-grade squamous intraepithelial neoplasia

(LSIL)(NIH,2001). The gynecological expertise to treat LSIL is not likely to be available for millions of women in developing countries and even after conventional treatment like laser, CO₂ vaporization, loop excision or conisation, recurrence may occur in about 5-30% of cases (Ramos et al, 2008; Melnikow et al, 2009).

Cervical cancer is usually a slowly developing neoplasm and screening methods like the Pap smear and HPV DNA test are available for early detection of precancer and cancer, hence there is a substantiable scope for chemoprevention (Sasieni, 2006; Weinberg, 2007). Apart from nutrients, antihormones, Vitamin A analogues, and COX-2 inhibitors, extracts of medicinal plants also have shown in vivo and in vitro anticancer activity and have been evaluated for secondary chemoprevention or as complementary therapy in advanced cancer (Hefler et al., 2006; Sasieni, 2006; Gullett et al., 2010; Vaidya et al., 2010a).

Bioactive compounds from turmeric or *Curcuma longa* Linn (C longa), specially curcumin, are known for chemopreventive activity (Kuttan et al, 1985; Nagabhushan & Bhide, 1987; Bhide & Jakhi, 1994;

¹Medical Research Center, Kasturba Health Society and ICMR Advanced Center of Reverse Pharmacology in Traditional Medicine, Vile Parle, Mumbai, ²Ayurvedya Prasarak Mandal's Ayurved Mahavidyalaya, Sion, Mumbai, ³Nisarga Biotech Pvt. Ltd., Satara, India *For correspondence: mrckhs@gmail.com

Hastak et al., 1997; Garg et al., 2008; Aggarwal & Sung, 2009). Earlier studies carried out by our team under the Reverse Pharmacology programme (Vaidya et al., 2010b) have demonstrated the activity and safety of Turmeric oil in experimental animals, rats and mice, and in healthy human volunteers or patients with Oral Submucous Fibrosis (Hastak et al., 1997; Ramachandran, 2000; Joshi et al., 2003). Other authors have reported antimicrobial, antifungal, and antioxidant activity of Turmeric oil (Jayaprakasha et al., 1999; 2002). Since LSIL is a common early precancerous lesion detected by Pap smears and cervical cancer can be prevented, we studied the potential chemopreventive activity of a standardized proprietary supercritical extract of turmeric rhizome (NBFR-03), in women with LSIL. The study was approved by an independent intersystem ethics committee.

Materials and Methods

Formulation development, standardization and quality control

An oral formulation was developed from the proprietary supercritical extract of turmeric rhizome (NBFR-03) which was standardized as per GMP requirement. CO₂ extraction is a preferred method of extraction as it retains temperature sensitive bioactive ingredients intact, does not have any hazardous solvent residues in the extract, and extract is free from heavy metals and microbes.

TLC, GC and HPLC were carried out. The extract was retested for heavy metals, pesticide content, microbial load and aflatoxin as per national and WHO guidelines for natural products (WHO, 2007; CCRAS, 2008). Accelerated stability and shelf life were studied for the formulation including variations in weight and extract content of the capsules. Gas chromatographic analysis of the extract from the formulation was carried out initially and after 12 months.

The accelerated stability of the formulation is carried out as per ICH guidelines. Stability is established using GC analysis for Turmerone content in the extract. The formulation is stable for a period of 3 years as per the ICH guidelines for accelerated test at 40° C at 75 percent relative humidity for a period of 6 months. Each capsule contained 0.2 gm of NBFR-03 .

Storage and Preservation

The capsules were preserved in brown bottles with silica gel packs under dry and cool conditions at room temperature, away from sunlight. A healthy volunteer study was carried out with the new formulation for safety, tolerability and acceptability.

Healthy volunteer study

This was carried out in 6 young healthy ambulatory subjects, aged 20 to 30 years under supervised conditions in the Ayurvedic Hospital. The volunteers were instructed

to report any aberrations in diet and physical activity. A special case record form was used to record symptoms, signs and daily drug compliance. Haematology including platelets, organ function tests for liver, and kidney, lipid profile, fasting sugar, serum proteins and routine urine analysis for proteins, sugar and microscopy, were carried out initially and at the end of 1 month of capsule intake. The laboratory participates in the National Quality Control programme.

Blood pressure, weight and clinical examination were carried out at 0, 8, 24 and 48 hours and weekly thereafter. The dose was 1 capsule daily X 1 week, 1 capsule BD X 1 week and 1 capsule TDS X 2 weeks orally after breakfast or meals. Since our previous study with same dosage of Turmeric oil, 0.2 gm capsules, had shown safety upto 3 months and the study in oral submucous fibrosis (OSMF) had also shown safety (Hastak et al, 1997; Joshi et al, 2003), this study with supercritical extract (NBFR-03) was restricted to 1 month.

Clinical study for chemopreventive activity in women with LSIL

Clinical setting: Women were enrolled from an outpatient Pap smear screening programme for women at the Medical Research Center- Kasturba Health Society and the Joint Leucorrhoea Clinic at Ayurved Mahavidyalaya Hospital, Sion. After screening they were advised treatment of infections; partner treatment was ensured in sexually active women.

Collection of Pap smears, micrometry, colposcopy: Pap smears were collected from each woman with a disposable spatula and endocervical brush and fixed immediately. Women with abnormal or unsatisfactory smears were advised repeat smears after treatment of genital infections. The Bethesda classification was followed for Pap smear diagnosis and infections were reported as has been described earlier (Joshi et al., 1993; 2001; Paradkar et al., 2010a). Colposcopy was carried out routinely in all cases with abnormal smears. Micrometry was carried out in cases with persistent LSIL under oil immersion lens with the micrometer as reported earlier and as described by other authors (Paradkar et al, 2010b; Bollmann et al, 2001; Steinman et al, 2008).

Treatment of genital infections: This was as per the international guidelines modified for Indian population in a general hospital (CDC, 2006; NIRRH, 2006) and if repeat smears showed persistent LSIL (Joshi et al, 2010) they were interviewed for participation in the research project. Twenty one women with inclusion/ exclusion criteria as given below, gave an informed written consent and agreed to participate in the study.

Inclusion criteria: 1) Persistent LSIL in Pap smears 2) Willingness to participate in the study and follow the schedule 3) Age between 25 and 65 years 4) Initial blood tests as described above for healthy volunteers, with additional serological tests for Thyroid Stimulating Hormone, Human Immunodeficiency Virus antibodies, serum Treponema pallidum antibody, and routine

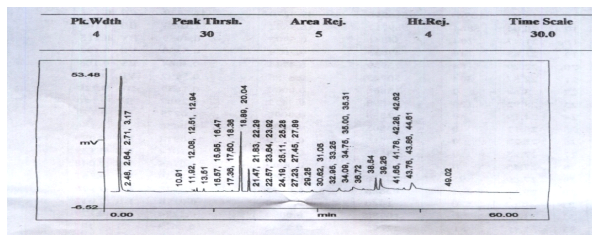


Figure 1. Gas Chromatographic Analysis of NBFR-03 Capsule Extract

urinalysis within normal limits.

Exclusion criteria: 1) High grade abnormal lesions in Pap smears 2) Pelvic inflammatory disease 3) Associated gynecological pathology like ovarian tumor, prolapse, polyp etc 4) Uncontrolled systemic disease 5) Food or drug allergies .

Dose: I capsule with 0.2 gm of standardized proprietary supercritical extract of turmeric rhizome (NBFR-03), twice daily, after breakfast and dinner for 12 weeks.

Follow up: Examination was scheduled after every 2 weeks or anytime they had complaints, however if they were not able to meet the schedule they informed in advance and collected extra drug supply for 2 weeks. Drug compliance was recorded. All participants reported at 4, 8 and 12 weeks with a margin of 3 - 5 days depending on their menstrual cyclicality. All were requested to come for the cytologic and colposcopic follow up in the post therapy period at 6 monthly intervals for at least 3 years. Serum IL-6 : Serum IL-6 was measured using a commercial kit (Biosource IL-6 EASIA kit; KAP 1261) as described earlier (Paradkar et al, 2010b) in study cases before and after treatment with NBFR-03 using an enzyme immunoassay standardized in our laboratory with intra-assay and inter-assay coefficients of variation <5%.

Results

Formulation development & standardization

The heavy metal content (mercury, lead , arsenic, and cadmium) and 20 pesticides including those used commonly in the area of cultivation of the plant, *C. longa*, were determined in a commercial registered laboratory. The microbial load and aflatoxin were within the permissible limits (data not shown), as required by World Health Organization and Central Council for Research in Ayurveda and Siddha, so also the manufacture of capsules, shelf life and labeling as per good manufacturing practices. Gas chromatogram of the supercritical extract , NBFR-03 showed peaks of α - turmerone and β - turmerone (Figure 1).

Healthy Volunteer Study

There were no significant symptoms or signs or biochemical alterations in 6 healthy volunteers due to NBFR-03 intake. The mean (\pm SD) weight of the volunteers was 60.6 \pm 9.39 kg before starting treatment

and 60.08 \pm 9.06 kg after 4 weeks of treatment. The mean systolic and diastolic blood pressures of volunteers were 115/76.7 mm Hg and 108/75 mm Hg respectively (paired t test; NS). There were no significant differences between the haematological parameters, liver functions, renal functions, lipid profile, serum proteins, fasting sugar and urinalysis in volunteers before and after NBFR-03 treatment.

Results of screening programme

A total of 1473 women participated in the screening programme. Prevalence of Low Grade Squamous Intraepithelial Lesions (LSIL) was 6.49 %, High -Grade Lesions (HSIL), 1.19 % and invasive Squamous Cell Carcinoma, 0.63%. All cases with high grade abnormalities were referred for colposcopy, biopsy and further management. Out of the cases with LSIL only those with persistent LSIL after antimicrobial therapy as described earlier (Joshi et al., 2010), and willing to follow the protocol, were invited to participate in the study and 21 were included for study as per the selection criteria after colposcopic exclusion of high grade CIN. Investigations included clinical examination, Pap smears, colposcopy , clinical biochemistry, urinalysis, and serum IL-6 measurement, before and after treatment. Standardised NBFR-03 (0.2 gm) capsule was administered, orally twice daily after breakfast and dinner, for 12 weeks.

Clinical assessment

The mean age of these cases was 41 \pm 2.5 (SEM) years and parity was 1.78 \pm 0.0 (SEM). They all belonged to the lower socioeconomic group. There was no significant difference in the mean blood pressure and weight of these cases before and after treatment (paired t test: NS).

Symptomatology: These cases were already treated with antimicrobials and were generally asymptomatic. Out of 21 cases enrolled for the study, 1 did not start medication as she left city due to personal emergency. Another discontinued within 1 week on her own due to mild itching without any rash. One case, who tolerated the treatment well and showed regression in Pap smear had to discontinue after 8 weeks as she had to go out of station. One case discontinued after 4 weeks due to haemorrhoids, and another, also at 4 weeks, due to suspected allergic reaction to an analgesic. She did not agree for a rechallenge. However both these cases had tolerated the treatment well and showed regression in Pap smear even within 4 weeks. The remaining 16 cases completed 12 weeks of treatment.

No abnormal clinical changes were observed during treatment in the general examination, systemic examination and gynecological check up. Three cases reported occasional aroma of turmeric in eructations , and 3 cases reported improvement in skin complexion after 4-8 weeks. No moderate or severe adverse events due to therapy were reported during treatment.

Compliance: Except in cases who discontinued for

Table 1. Pap Smear and Colposcopy in 19 Cases Before and After Treatment with NBFR-03

Report	Before treatment	After treatment
Pap Smear*		
LSIL	19	4
ASCUS		4
Atypia		5
Inflammatory		5
Colposcopy*#		
CIN II		
CIN I	10	4
? CIN I	3	6
Negative	6	7

* One patient discontinued after 1 week; *# Not possible in one case after treatment

Table 2. Nuclear Diameter, Nucleocytoplasmic(N/C) Ratio and % Cells with Coarse Chromatin Before and After Treatment with NBFR-03 (N=18)

	Nuclear diameter*		N/C Ratio**		% Cells with coarse chromatin	
	Before	After	Before	After	Before	After
Mean	13.52	12.14	0.28	0.23	12.6	6.89
SD	1.96	1.72	0.06	0.05	9.43	7.65
SEM	0.46	0.41	0.01	0.01	2.22	1.8

Paired t test: p value *<0.02; **<0.05; *** p<0.01

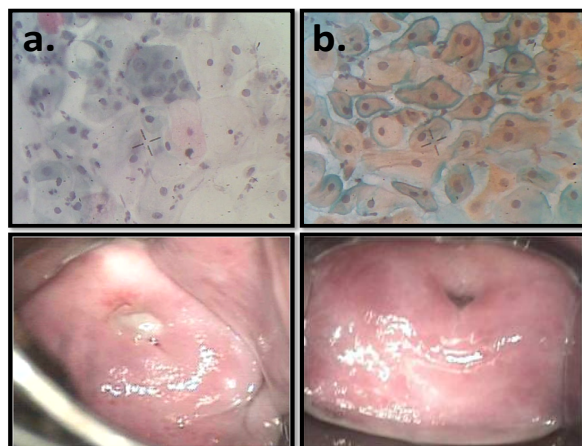


Figure 2. Pap Smear & Colposcopy in Case no 2. a) Persistent LSIL after antimicrobial treatment; b) ASCUS after treatment with NBFR-03

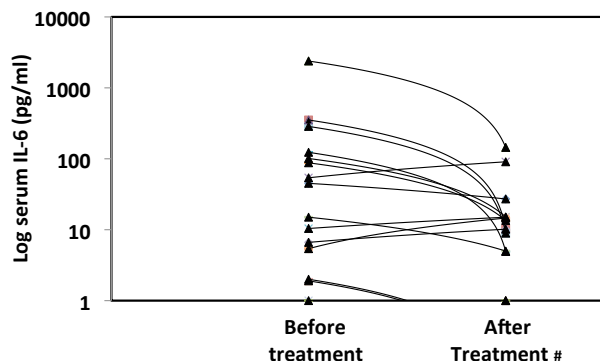


Figure 3. Serum IL-6 levels in 16 cases of LSIL before and after treatment with NBFR-03. # Before vs After- p<0.05, Wilcoxon rank test, two tailed

reasons described above, drug compliance was more than 95% as assessed by history and counting of the balance number of capsules returned at each visit.

Clinical biochemistry: The mean haemoglobin was 11.7±0.36gm (SEM)/dl and 11.6±0.30gm (SEM)/dl before and after study (paired t test , NS). The blood counts and all organ function tests, including Thyroid stimulating hormone, did not change significantly during the treatment period (data not shown).

Pap smears, colposcopy and cytometry

None of the cases, who had persistent LSIL after antimicrobial treatment, progressed to HSIL or cancer during 12 weeks of therapy as assessed by Pap smear and colposcopy (Table 1). Out of the 19 cases who had evaluation before and after therapy 16 regressed to lower degree of abnormality or negative status. Three cases showed persistence of LSIL but of a minimal borderline nature. Colposcopy showed changes of CIN 1 in 10 out of 19 cases before treatment, but only in 4 out of 19 cases after treatment (Table 1, Figure 2 a,b).

There was a significant reduction in nuclear diameters (paired t test; p<0.02), Nucleocytoplasmic (N/C) ratios (p<0.05) and percentage of cells with coarse chromatin (p<0.01) in these cases after treatment with NBFR-03(Table 2).

Serum IL-6 levels: The mean serum level was 248.5 ± 156.4 (SEM) pg /ml before treatment and 27.7 ± 10.5 (SEM) pg /ml after treatment with NBFR-03 in LSIL cases (N=16) (p< 0.05, Wilcoxon Rank Test, 2 tailed). After exclusion of the case no 5 with an outlying initial value of 2388 pg/ml , the p value with the paired t test was 0.06. Even in this case the IL-6 levels were markedly reduced to 144 pg /ml post treatment. However in 8 of these LSIL cases serum levels were within normal limits initially and in 7 cases post treatment also. In one of these cases there was a rise of 50 pg/ml in 3 months.

Long term follow up: Out of 19 cases 13 have come for follow up from 6 to 36 months after discontinuation of NBFR-03 treatment. They have not had any other treatment for LSIL in the intervening period. Their repeat Pap smears show that 10 cases have remained in the regressed stage, 3 continued to be in the LSIL stage, however none progressed to higher grade. These findings were confirmed by colposcopy. Of the remaining 6 cases 2 have given a telephonic follow up that they are asymptomatic but are unable to come for a clinic visit and 2 are awaiting the 6 monthly follow up. Two cases are lost to follow up as they went out of city.

Due to the limited budget it was not possible to carry out HPV DNA studies but 13 out of 21 cases had HPV related cytologic abnormalities like koilocytosis, hyperkeratosis, parakeratosis and orangophilia.

Discussion

In cervical cancer is the terminal event in the process of carcinogenesis which usually starts in

the basal epithelium of cervix, commonly at the squamocolumnar junction. There are multiple changes which may occur sequentially or simultaneously and which cause dedifferentiation and uncontrolled proliferation before the invasive stage is attained. In majority of cervical cancers this process, involving initiation, promotion and invasion, may take from 10 to 13 years (Weinberg, 2007). There is therefore ample opportunity for chemoprevention. Although several agents have been used in chemoprevention trials such as retinoic acid derivatives including 4-HPR, indole-3 carbinol, α -difluoromethylornithine (DFMO), refocoxib, resveratrol, cisplatin, panex-ginseng-3 extract, curcumin, selenium, 5-fluorouracil, epigallocatechin and folic acid, none has shown total arrest or reversal (Bell et al., 2000; Cheng et al., 2001; RelaFollen et al., 2002; Alvarez et al., 2003; Abu et al., 2005; Kim et al., 2005; Hefler et al., 2006; Sasieni, 2006; Bar-Sela et al., 2010; Gullett et al., 2010). However these trials included both low and high grade neoplasias.

The mechanisms through which these agents may act are varied and extend from the stage of initiation to invasion and many agents are also used for palliation or for complementary therapy to prevent side effects of chemotherapy or radiotherapy. Turmeric products have been shown to have multiple anticancer mechanisms such as DNA protective, antioxidant, anti-inflammatory activity, inhibition of NFkB pathway, inhibition of telomerase, isotopomerase and several other pathways contributing to genetic mutation, inhibition of apoptosis and uncontrolled mitosis (Hastak, 1997; Pardo-Govea, 2005; Garg, 2008; Aggarwal & Sung, 2009). Recently HPV specific pathways such as HPV transcription and AP-1 activity and downregulation of viral oncogenes have been shown to be inhibited by curcumin (Prusty and Das, 2005; Divya & Pillai, 2006).

In the present study none of the cases progressed to a higher degree of abnormality during 12 weeks of NBFR-03 therapy. This is very encouraging. Additionally there was regression in 16 cases which was maintained in the post-therapy follow up, thus indicating that the pretreatment of genital infections with antimicrobials followed by NBFR-03 therapy is likely to have a long lasting effect. In 5 cases there was total regression to a mild inflammatory pattern, and in 5 cases, mild inflammatory Atypia, which was maintained post-therapy. Colposcopy findings corroborated the cytology findings, particularly in excluding a higher grade lesion which requires a cervical biopsy for evaluation.

The role of various Interleukins such as IL-1, IL-2, IL-4, IL-6, IL-8, IL-10, and IL-12 in cancer has been investigated by several authors, particularly IL-4, IL-6, IL-8, IL-10, and IL-12 in cervical cancer cell lines. The interleukins act directly on cancer cell receptors to promote mitosis, to inhibit apoptosis, and promote angiogenesis by attracting other leucocytes which produce growth factors. Thus they can influence each stage of carcinogenesis including infiltration and

metastasis. Elevated levels of IL-6 are associated with a poor prognosis in lymphomas and multiple myeloma and a decline is associated with partial remissions (Murooka et al., 2005). Serum levels of IL-6 are reported to be elevated in gynecological cancers and precancer. IL-6 levels are known to be elevated in cervicovaginal fluid and in circulation, in cervical biopsy specimens of cervical intraepithelial neoplasia in LSIL as well as HSIL and invasive cancer (Tjiong et al., 1999; Pardo-Govea et al., 2005; Heikkila et al., 2008; Paradkar et al., 2010b). In the rat model of chemically induced cervical carcinogenesis it was observed that IL-6 was increased in cervical biopsy sections and in circulating blood as the degree of precancer advanced and as the lesion became invasive (Bustamam et al., 2008).

In the present study a significant reduction in serum IL-6 levels was observed after treatment with NBFR-03. This may signify a reversal of the progressively chronic inflammatory process in these cases. NFkB is activated in carcinogenesis. It induces the expression of IL-6 which is an autocrine factor secreted by transforming cells for their growth and survival. Additionally NFkB also plays an important role in the antiapoptotic signaling in a number of cancer cell types. Inhibition of NFkB could be a major contributory mechanism of anticancer activity of bioactive turmeric compounds. NFkB also activates TNF-alpha gene which is a growth factor. COX-2 inhibition is another possible mechanism of anticancer activity, as is shown with curcumin. These pathways need to be investigated further for elucidating the exact mechanism of action.

Chronic infection with High Risk HPV is a known carcinogenic initiator for cervical cancer. However all cases with HR HPV do not undergo transformation. Gangawar et al (2009) have shown the association of IL-6 gene mutation with cervical cancer and this may explain why some cases with HR-HPV progress to cancer whilst others do not. Recently anticancer activity of essential oil of *Curcuma longa* or Turmerone has been reported in vitro or in vivo (Aratanechemuge et al., 2002; Li et al., 2009; Lim et al., 2010; Yue et al., 2010; Chen et al., 2011).

The follow up in 13 cases shows that the combined effect of treatment of STIs and NBFR-03 is likely to persist and indicates the need to investigate this compound further for cervical cancer chemoprevention.

Although it is desirable to study local IL-6 levels this was not possible in the present study as this requires expensive equipment and standardization. On the other hand measurement of circulating IL-6 is standardized in our laboratory. No cervical biopsy was carried out in study subjects as repeat Pap smears after treatment with antimicrobials, in all of them showed persistent LSIL confirmed by colposcopy. Further, after treatment with NBFR-03 for 12 weeks, and at subsequent follow ups, there was arrest or regression of the Pap smears and colposcopy in all cases. Due to limited finances it was not possible to include High Risk HPV DNA testing however out of 21 cases 13 had HPV related cytologic

abnormalities. Moreover under conditions of remission HPV DNA tests may be negative and there is variation in the sensitivity and specificity of different tests (Basu et al., 2011) and it may not be possible to comment unless long term follow up results with HR HPV DNA are conducted. This increases the cost of investigations significantly.

Turmeric oil is usually discarded as a byproduct of the curcumin industry. Studies conducted by our team earlier and recently in other centers also have shown that it has anticancer potential and can be used clinically. The oral administration of NBFR-03, an oleoresin free supercritical extract of the turmeric rhizome, rich in Turmerone content, was associated with arrest of progression in all 19 LSIL cases who took the treatment for 1 to 3 months, and with regression in 16 cases, thus indicating potential chemopreventive activity. An anti-inflammatory activity associated with reduction in circulating levels of IL-6, a potential biomarker for chemopreventive clinical trials, could be one of the mechanisms of action of the NBFR-03 Turmeric oil extract.

Acknowledgement

We are grateful to Dr MZ Affandi, consultant cytopathologist for screening support. We thank 1) Kasturba Health Society, Wardha, Maharashtra, for infrastructure support, 2) Department of Biotechnology, Govt of India, for research project grant and 3) Ayurvediya Prasarak Mandal, Sion for Ayurvedic collaboration. The Turmeric oil capsules were supplied by Nisarga Biotech Private Limited, Satara. Part of the data was presented at the conference of the Asia Pacific Organization for Gynecological Infections & Neoplasia (AOGIN Indian Chapter), November 2011, Mumbai.

References

Abu J, Batuwangala M, Herbert K, Symonds P (2005). Retinoic acid and retinoid receptors: potential chemopreventive and therapeutic role in cervical cancer. *Lancet Oncol*, **6**, 712-20.

Aggarwal BB, Sung B (2009). Pharmacological basis for the role of curcumin in chronic diseases: an age-old spice with modern targets. *Trends Pharmacol Sci* **30**,85-94.

Aratanechemuge Y, Komiya T, Moteki H et al (2002). Selective induction of apoptosis by ar-turmerone isolated from turmeric (*Curcuma longa* L) in two human leukemia cell lines, but not in human stomach cancer cell line. *Int J Mol Med*, **9**, 481-4.

Bar-Sela G, Epelbaum R, Schaffer M (2010). Curcumin as an anti-cancer agent: review of the gap between basic and clinical applications. *Curr Med Chem*, **17**, 190-7.

Basu P, Chandna P, Bamezai RN et al (2011). MassARRAY spectrometry is more sensitive than PreTect HPV-Proofer and consensus PCR for type-specific detection of high-risk oncogenic human papillomavirus genotypes in cervical cancer. *J Clin Microbiol*, **49**, 3537-44.

Bell MC, Crowley-Nowick P, Bradlow HL et al (2000). Placebo-controlled trial of indole-3-carbinol in the treatment of CIN. *Gynecol Oncol*, **78**, 123-9.

Bhide SV, Jakhi SD (1994). Clinical studies on turmeric treatment of precancerous oral lesions. Proceedings of XVI. International Cancer Congress. Abstract 351.

Bollmann R, Bollmann M, Henson DE et al (2001). DNA cytometry confirms the utility of the Bethesda system for the classification of papanicolaou smears. *Cancer*, **93**, 222-8.

Bustamam A, Ibrahim N, Devi N et al (2008). The Establishment and Use of an in vivo Animal Model for Cervical Intra-Epithelial Neoplasia. *International Journal of Cancer Research*, **4**, 61-70.

Center for Disease Control (CDC) (2006). Sexually Transmitted Diseases Treatment Guidelines. MMWR August 4, 2006 / 55(RR11);1-94.

Central Council for Research in Ayurveda & Siddha. Guidelines for formulation development. http://www.ccras.nic.in/Training_Modules/20081103_DrugStandardization2.htm

Chen W, Lu Y, Gao M et al (2011). Anti-angiogenesis effect of essential oil from *Curcuma zedoaria* in vitro and in vivo. *J Ethnopharmacol*, **7**, 220-6.

Cuzick J, Castañón A, Sasieni P (2010). Predicted impact of vaccination against human papillomavirus 16/18 on cancer incidence and cervical abnormalities in women aged 20-29 in the UK. *Br J Cancer*, **102**, 933-9.

Divya CS, Pillai MR (2006). Antitumor action of curcumin in human papillomavirus associated cells involves downregulation of viral oncogenes, prevention of NFkB and AP-1 translocation, and modulation of apoptosis. *Mol Carcino*, **45**, 320-32

Gangawar R, Mittal B, Mittal RD (2009). Association of interleukin-6 -174G>C promoter polymorphism with risk of cervical cancer. *Int J Biol Markers*, **24**, 11-6.

Garg R, Gupta S, Maru GB (2008). Dietary curcumin modulates transcriptional regulators of phase I and phase II enzymes in benzo[a]pyrene-treated mice: mechanism of its anti-initiating action. *Carcinogenesis*, **29**, 1022-32.

Gullett NP, Ruhul Amin AR, Bayraktar S et al (2010). Cancer prevention with natural compounds. *Semin Onco*, **37**, 258-8.

Hastak KA, Lubri N, Jakhi SD et al (1997). Effect of turmeric oil and turmeric oleoresin on cytogenetic damage in patients suffering from oral submucous fibrosis. *Cancer Letters*, **116**, 265-269.

Hefler LA, Grimm C, Speiser P et al (2006). The cyclooxygenase-2 inhibitor rofecoxib (Vioxx) in the treatment of cervical dysplasia grade II-III: A phase II trial. *Eur J Obstet Gynecol Reprod Biol*, **125**, 251-4.

Heikkila, Ebrahim S, Lawlor DA (2008). Systematic review of the association between circulating interleukin-6 (IL-6) and cancer. *Eur J Cancer*, **44**, 937-45.

Jayaprakasha GK, Jena BS, Negi PS, Sakariah KK (2002). Evaluation of antioxidant activities and antimutagenicity of turmeric oil: a byproduct from curcumin production. *Z Naturforsch [C]*, **57**, 828-35.

Jayaprakasha GK, Negi PS, Anandharamkrishnan C,

- Sakariah KK (2001). Chemical composition of turmeric oil--a byproduct from turmeric oleoresin industry and its inhibitory activity against different fungi. *Z Naturforsch [C]*, **56**, 40-4.
- Jin L, QiM, Chen DZ, Anderson, et al (1999) . Indole 3-carbinol prevents cervical cancer in human papilloma virus type 16 (HPV 16) transgenic mice. *Cancer Res*, **59**, 3991-3997.
- Joshi JV, Affandi MZ, Amin P et al (2010). Persistence of cytologic abnormality after treatment of bacterial, parasitic and fungal infections in older women with low grade squamous intraepithelial lesion. *Acta Cytol*, **54**, 242-3.
- Joshi JV, Ghaisas SD, Vaidya RA et al (2003). Early clinical safety study with turmeric oil (*Curcuma longa* oil) in human volunteers. *J Med Assoc Ind*, **51**,1055-1060.
- Joshi JV, Mali BN , Bhave G, Wagle U (1993). Cervical neoplasia and cytological manifestations of sexually transmitted infections in HIV seropositive prostitutes. *Diagnostic Cytopathology*, **4**, 63-64.
- Joshi JV. Detecting *Chlamydia trachomatis* infection in women (2001). *Acta Cytologica*, **46**, 890-891.
- Kim HG, Yamal JM, Xu XC et al (2005). Cervical chromosome 9 polysomy: validation and use as a surrogate endpoint biomarker in a 4-HPR chemoprevention trial. *Gynecol Oncol*, **99**(3 Suppl 1), S32-7.
- Kuttan R, Bhanumathy P, Nirmala K, George MC (1985). Potential anticancer activity of turmeric (*Curcuma longa*). *Cancer Letters*, **29**,197-202.
- Li Y, Wo JM, Liu Q et al (2009). Chemoprotective effects of *Curcuma aromatica* on esophageal carcinogenesis. *Ann Surg Oncol*, **16**, 515-23.
- Lim CB, Ky N, Ng HM et al (2010). *Curcuma wenyujin* extract induces apoptosis and inhibits proliferation of human cervical cancer cells in vitro and in vivo. *Integr Cancer Ther*, **9**, 36-49.
- Melnikow J, McGahan C, Sawaya GF et al (2009). Cervical intraepithelial neoplasia outcomes after treatment: long-term follow-up from the British Columbia Cohort Study. *J Natl Cancer Inst*, **101**, 721-8.
- Moore MA, Ariyar Y, Badar F et al (2010). Cancer epidemiology in South Asia - past, present and future. *Asian Pac J Cancer Prev*, **11** (Suppl 2), 49-66.
- Murooka TT, Ward SE, Fish EN. Chemokines and Cancer (2005). Chapter 2. In: Cytokines and Cancer, Ed; Platanius LC, Springer, pp 15-44.
- Nagabhushan M, Bhide SV (1987). Antimutagenicity and anticarcinogenicity of turmeric (*Curcuma longa* Linn). *J of Nutrition Growth & Cancer*, **4**, 83-89.
- National Institute of Research in Reproductive Health (2006). National Guidelines for Diagnosis and Treatment and Management of Reproductive Tract Infections/ Sexually Transmitted Infections in Primary Health Care, Indian Council of Medical Research, 2006.
- National Institutes of Health (NIH), Bethesda Workshop Proceedings (2001). Bethesda system for reporting cervical/vaginal cytologic diagnosis . *Acta Cytol*, **37**, 115-24.
- Negi PS, Jayaprakasha GK, Jagan Mohan Rao L, Sakariah KK (1999). Antibacterial activity of turmeric oil: a byproduct from curcumin manufacture. *J Agric Food Chem*, **47**, 4297-300.
- Paradkar PH, Agashe S, Joshi JV et al (2010a). Serum Cytokine levels and micrometry of Pap smears in women with leucorrhoea and with Low Grade Cervical Intraepithelial Lesions (LGSIL). *Asia Pac J of Cancer Prev*, **11**, 989-992.
- Paradkar PH, Godse CG, Joshi JV et al (2010b). Use of mobile camera photography for quick scientific communication for early diagnosis and prevention of cervical cancer. *J MGIMS*, **15**, 41-44.
- Pardo-Govea T, Callejas D, Núñez-Troconis J et al (2005). Gamma interferon (IFN-gamma), tumor necrosis factor alpha (TNF-alpha) and interleukins 2, 4 and 6 (IL-2, IL-4, IL-6) in cervical-uterine cells of intraepithelial neoplasia: a preliminary report. *Invest Clin*, **46**, 5-13.
- Prusty BK and Das BC (2005). Constitutive activation of transcription factor AP-1 in cervical cancer and suppression of human papillomavirus (HPV) transcription and AP-1 activity in HeLa cells by curcumin. *Int J Cancer*, **113**, 951-960.
- Ramachandran Rejina (2000). Study of Turmeric oil: Organ Specific Safety and Activities. M. Sc. Dissertation University of Mumbai.
- Ramos MC, Pizarro De Lorenzo BH et al (2008). High-grade cervical intraepithelial neoplasia, human papillomavirus and factors connected with recurrence following surgical treatment. *Clin Exp Obstet Gynecol*, **35**, 242-7.
- Sankaranarayanan R, Boffetta P (2010). Research on cancer prevention, detection and management in low- and medium-income countries. *Ann Oncol*, **21**,1935-43.
- Sasieni P (2006). Chemoprevention of cervical cancer. *Best Pract Res Clin Obstet Gynaecol*, **20**, 295-305.
- Steinman S, Smith D, Chandler N et al (2008). Morphologic, patient and interpreter profiles of high-risk human papillomavirus-positive vs.-negative cases of atypical squamous cells of undetermined significance. *Acta Cytolo*, **52**, 279-85.
- Tjong MY, van der Vange N, ten Kate FJ et al (1999). Increased IL-6 and IL-8 levels in cervicovaginal secretions of patients with cervical cancer. *Gynecol Oncol*, **73**, 285-91.
- Vaidya ADB, Amonkar AJ, Bhatt NS, Parikh PM (2010a). Complementary and Alternative Medicine for Cancer Care in India: Basic and Clinical Perspective . Chapter3. In: Alternative & Complementary Therapies for Cancer: Integrative Approaches and Discovery of Conventional Drugs. Ed. Moulay Alaoui-Jamali, Springer, 31-82.
- Vaidya AB, Vaidya RA (2010b). Roots of modern drugs in Reverse Pharmacology. In: Medicine Update, Ed. M. S. RAo, Association of Physicians of India(API), 2010, 871-879.
- Weinberg Robert A (2007). Multistep tumorigenesis. Chapter 11. In: The Biology of Cancer. Garland Science, 399-462.
- World Health Organisation (2007). WHO guidelines for assessing quality of herbal medicines with reference to contaminants and residues. WHO, Geneva, 2007.
- Yue GG, Chan BC, Hon PM et al (2010). Evaluation of in vitro anti-proliferative and immunomodulatory activities of compounds isolated from *Curcuma longa*. *Food Chem Toxicol*, **48**, 2011-20.